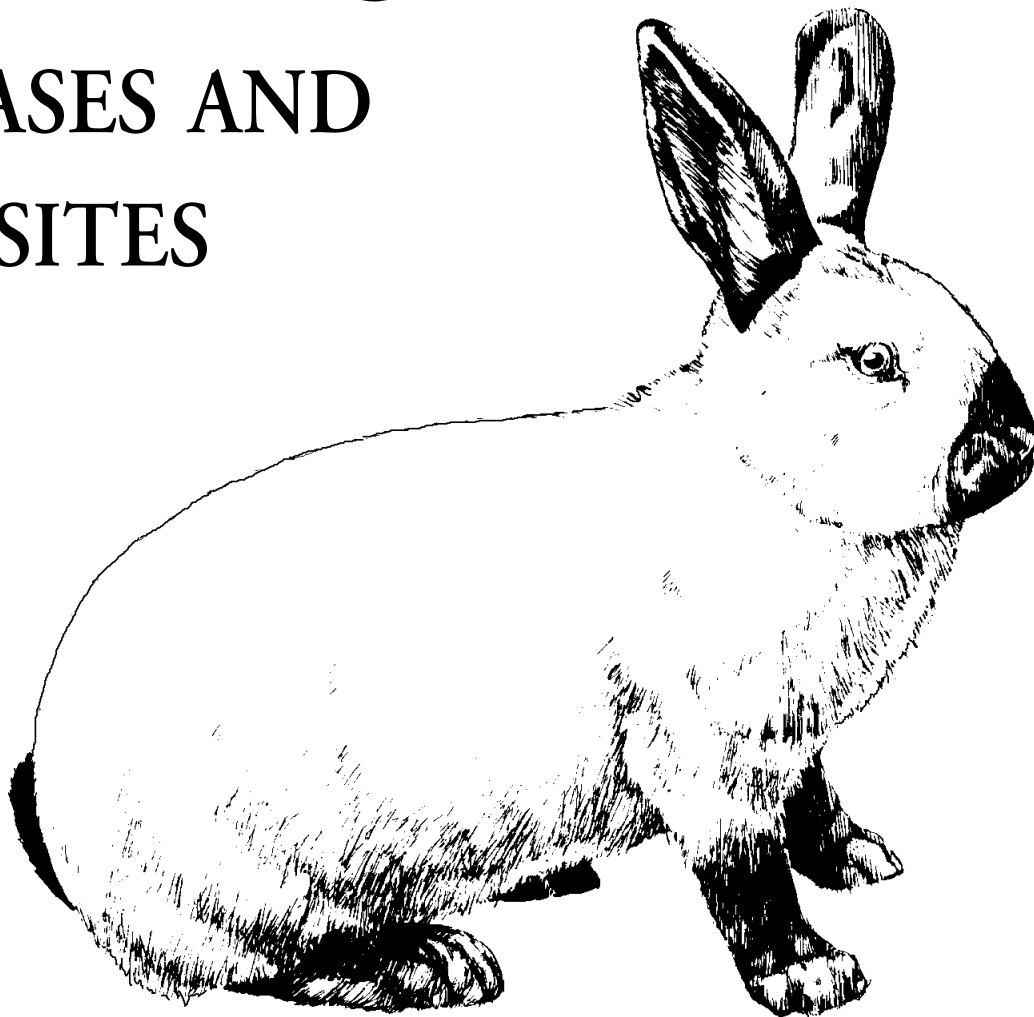


DOMESTIC RABBITS

DISEASES AND PARASITES



A Pacific Northwest Extension Publication
Oregon • Idaho • Washington

Contents

<i>Factors in disease prevention and control</i>	4	<i>Fungal diseases</i>	18
Body soundness and livability.....	4	<i>Parasitic diseases</i>	19
Adequate nutrition	4	Prevention and control	19
Suitable environment	4	External parasites.....	20
Prevention, eradication, and control of transmissible diseases.....	5	Ear mites.....	20
Sanitation program.....	5	Fur mites.....	20
Disinfection	6	Cuterebrid flies.....	20
Practices to maintain health and prevent disease.....	7	Fleas and ticks	21
<i>Bacterial diseases</i>	7	Internal parasites	21
Pasteurellosis	7	Coccidiosis	21
Rhinitis (snuffles)	7	Encephalitozoonosis	22
Pneumonia.....	8	Toxoplasmosis	23
Pyometra.....	8	Roundworms.....	23
Orchitis.....	9	Tapeworms.....	24
Otitis media	9	<i>Nutritional diseases</i>	25
Subcutaneous abscesses.....	9	Pregnancy toxemia	25
Septicemia.....	9	Vitamin A deficiency.....	25
Enteritis	9	Vitamin E deficiency	25
Enterotoxemia	9	<i>Hereditary diseases</i>	26
Mucoid enteropathy	10	Glaucoma.....	26
Tyzzer's disease	10	Malocclusion.....	26
Coccidiosis.....	11	Splay leg and ataxia	26
Listeriosis	11	<i>Miscellaneous</i>	27
Necrobacillosis	11	Cannibalism.....	27
Salmonellosis.....	12	Heat prostration.....	27
Staphylococcosis.....	12	Broken back	27
Mastitis	13	Sore hocks.....	28
Conjunctivitis (weepy eye)	13	Tumors.....	28
Treponematosis (vent disease).....	13	Fur eating and hairballs	28
Hutch burn	14	Coprophagy	29
Pseudotuberculosis	14	Yellow fat	29
Tularemia	14	Winter breeding depression	29
<i>Viral diseases</i>	15	<i>How to pack and ship specimens for laboratory diagnosis</i>	29
Myxomatosis	15	Shipping dead animals.....	29
Rabbit pox	16	Accompanying information.....	30
Fibroma	16		
Herpes virus infection	16		
Rabbit papilloma.....	16		
Oral papilloma	16		
Viral enteric diseases.....	17		
Viral hemorrhagic disease	17		

Domestic Rabbits: Diseases and Parasites

N.M. Patton, K.W. Hagen, J.R. Gorham, and R.E. Flatt

Domestication of the European rabbit probably occurred in monasteries during the Middle Ages. By the middle of the 17th century, rabbits were commonly raised in England and continental Europe. *Oryctolagus cuniculus*, one of the more successful mammals of the world, is both prolific and adaptable.

Most of the fancy breeds were developed within the past 100 years, and only since the early 1900s have rabbits been raised domestically in the United States. The first commercial colonies were started in southern California. Meat rationing during World War II gave the infant industry a push.

Today, approximately 200,000 people are engaged in some phase of the rabbit business in the United States, and animals are produced in every state. Meat processors serving major cities market more than 10 million pounds of rabbit meat annually. Over the years, the breeds have

been improved from the long, rangy, low-meat-yield type to the compact, blocky animal of today.

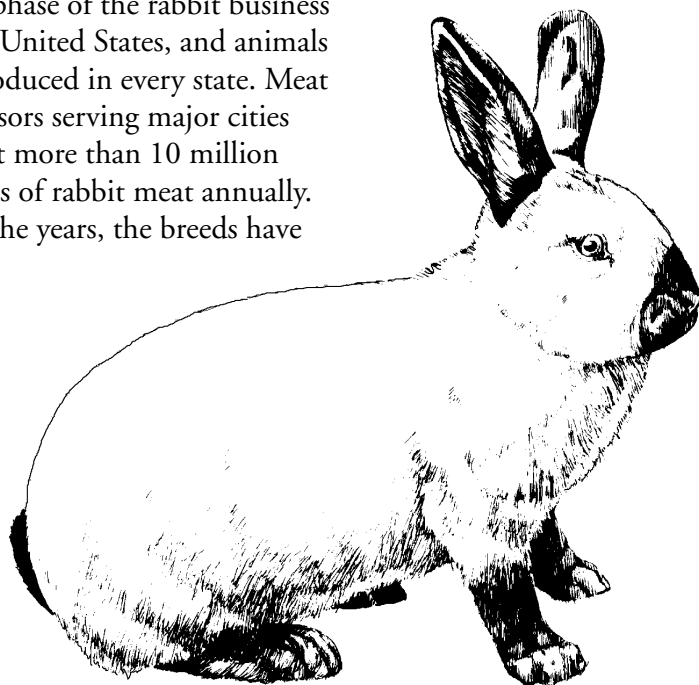
The offspring of one doe yield more than 120 pounds of meat per year, and 200 pounds per doe is not unlikely in the future. Feed required to produce 1 pound of meat has been reduced from about 6 pounds to 3.5 or 4 pounds.

During the past 10 years, the rabbit industry has expanded considerably. It may not, as yet, have reached the popularity it experienced during World War II. But the nutritional qualities of rabbit meat are making rabbit more acceptable, and production is increasing.

Rabbit raising has continued to be a backyard or part-time business. However, the size of the herds has expanded from a few does to the current average rabbit herd of 20 does, and it is not uncommon to see herds of 300–500 breeding does.

Commercial rabbitries averaging fewer than 30 rabbits per cage per year (sent to market) find it very difficult to show a profit. Typically, the profitable commercial number is more than 40 rabbits per cage per year.

As in all facets of agriculture, the profits from rabbit raising depend a great deal on management and market. If an area has a steady demand for rabbit meat and a stable processor, the rabbit farmer can net a reasonable profit and add to the family income.



Nephi M. Patton, director emeritus, Rabbit Research Center, Oregon State University; *Karl W. Hagen* (deceased), bacteriologist, and *John R. Gorham*, veterinarian, Agricultural Research Service, U.S. Department of Agriculture, Pullman, Washington; and *Ronald E. Flatt* (deceased), veterinarian, Department of Veterinary Pathology, Iowa State University. Revised in 2007 by John Harkness, professor emeritus, Mississippi State University. This publication is a revision of USDA Agriculture Handbook 490, originally published in 1976. It was prepared with the support and permission of the Agricultural Research Service.

The difference between profit and loss often comes down to a person's ability to master the husbandry and disease control techniques necessary for success. The only rabbit that will return a profit to its owner is a healthy one. This publication is designed to help ranchers recognize the more common rabbit diseases and to know when professional advice is needed. Diseases are classified according to major cause—bacterial, viral, nutritional, hereditary, fungal, and miscellaneous (including poisoning, tumors, and vices).

Factors in disease prevention and control

Factors conducive to good health include body soundness and livability; adequate nutrition; suitable environment; and prevention, eradication, and control of transmissible diseases.

Body soundness and livability

Sound, vigorous rabbits are necessary both as quality meat products and as replacement stock. Carefully examine the background of animals saved for breeding so that recognizable defects are not perpetuated. A healthy, mature breeder—one that has a history of several litters showing fast development, good reproduction, high livability of the young, and relative freedom

from disease—is a better source of replacement stock than a rabbit that does not show these traits.

Healthy, well-framed, well-fleshed mature does producing litters containing from 8–12 live young, with low mortality at 8 weeks, good feed conversion, and high weights are potential sources of breeding stock. Carefully examine each individual selected for breeding. Look for defects and general health, and eliminate animals that deviate from normal. Through rigid application of this practice, a profitable, high-producing herd can be established.

Adequate nutrition

Feeding is the most important husbandry technique in the rabbitry and should be done by an experienced person. Most disease and potential disease problems are discovered during feeding time. Some disease problems can be corrected by changing the amount or type of feed.

Much has been learned in the past few years concerning rabbit nutrition. Diets that produce good growth in poultry and swine are disastrous in rabbits. Rabbits are foraging animals that live on grasses and seeds in the wild. Their digestive system and its microbes do not adapt well to high-energy, cereal-grain diets.

In fact, diets high in starch and carbohydrates often cause diarrhea and death in fryer

rabbits. A simple change to a diet higher in fiber and lower in energy gives adequate growth without the risk of enteric disease.

On the other hand, does need adequate energy for reproduction, which may not be provided by diets extremely high in fiber. Progressive rabbit raisers now feed two diets, one to the growing fryers and another to the producing does. A simple diet that provides good health, growth, and production is preferred but often difficult to find because the needs of the various classes of rabbits are considerably different.

Inadequate nutrition is a costly problem. A general decline in health may increase susceptibility to diseases, which can lead to large monetary losses. In addition, young rabbits grow slowly if the doe has inadequate milk or they do not get enough feed. Thus, feeding is a critical element in successful rabbit raising.

Suitable environment

The term “environment” includes every factor that influences a rabbit's life. Some of these factors are hutch size and location, nearness to other animals, dryness, temperature, ventilation, amount of light, shelter design, availability of water, and general management. Careful examination and control of the environment are essential for effective disease prevention.

Prevention, eradication, and control of transmissible diseases

If disease prevention has failed and transmissible diseases are established in a rabbitry, high mortality may lead to business failure. Growers commonly encounter pasteurellosis, ear mange, and coccidiosis. These infectious diseases usually are introduced by contact with infected rabbits or by contaminated mechanical carriers.

Pasteurellosis and liver coccidiosis are important diseases spread by contact. Adult rabbits are the most important contact carriers. An animal may seem to recover from a disease but still shed infectious organisms in its feces, urine, or in droplets exhaled while breathing. Introducing new stock directly to a herd or exhibiting animals at shows and fairs increases the risk of disease outbreaks. Keep new or exhibition animals in a special isolation section of the colony until you are reasonably certain they are disease-free. This quarantine period usually is at least 2 weeks.

Carriers of disease often are not recognized because they seem healthy. Tests to pinpoint which animals are carriers are not always practicable. Liver coccidiosis is found when the fryer is dressed out for market, too late to trace back to the doe that produced it. Bacterial cultures of the nasal cavity may show

the presence of *Pasteurella*, but cultures usually cost too much to be used routinely.

Mechanical transmission of disease occurs when the infectious agent is carried accidentally from place to place. People are the chief offenders. The grower who treats a sick animal and then moves on to check or count newborn young can be an important carrier of respiratory infection and coccidiosis. Feed salespeople, service representatives, rabbit buyers, and others who have visited other rabbitries may be sources of infection. Avoid visiting other rabbitries where disease is present. These examples might seem extreme, but they happen repeatedly and are definite factors in introduction of disease. Dogs, cats, birds, and rodents have been incriminated in carrying diseases to rabbits and should be kept out of the rabbitry. Insects also should be controlled.

When disease prevention fails, you must consider how to control and eliminate the disease. When liver coccidiosis is involved, the adult carrier may be freed from infection by chemotherapy, but improved management practices are the only way to eliminate the disease from the herd.

In some cases, it may be necessary to depopulate to eliminate a disease. The time between depopulation and repopulation with clean, healthy animals depends on many factors. Envi-

ronment plays an important part in the time interval involved.

Sanitation program

A constant sanitation program is an important part of disease prevention. Cleanliness is required to establish and maintain a safe environment in which animals can live and reproduce. Elimination of disease carriers is most important.

Environmental factors must be considered in any sanitation program. Unfavorable environmental factors lower animals' resistance to disease and facilitate the spread of infection. Particularly important are hutch and shelter construction and maintenance (*Figure 1, next page*). Ease of cleaning, a supply of clean water, and space for rodent-proof feed storage are important. Proper drainage is another factor. Provide for water runoff from the rabbitry area. Construct hutches so that individual units may be removed for disinfecting. Adjust the number of animals per unit based on the area and the environment.

Water should be fresh, clean, and protected from contamination by urine, fecal matter, and feeds. It is important to clean water containers frequently.

Feed contaminated with feces may act as a mechanical carrier for infection. Protecting the feed from contamination by the use of properly designed and well-constructed feed hoppers is necessary in any good sanitation program. Clean feeders periodically.




Figure 1.—Shed construction suitable for mild climates.

Good feed utilization and waste removal are important in disease prevention. Feed scattered about the rabbitry attracts insects, mice, rats, and birds—all potential carriers of disease. Store bulk feed properly. In small rabbitries or where large quantities of bulk feed are not stored, metal garbage cans with tight lids are good feed-storage containers.

Disinfection

Disinfection refers to the killing of infectious agents such as bacteria, viruses, and parasites. To facilitate the use of disinfectants, all equipment and other construction should be as simple and easy to clean as possible.

Fecal matter and other organic material protect disease-producing bacteria, viruses, and parasites and nullify the

effectiveness of even the most efficient disinfectants. Thorough scraping and washing should precede disinfection.

A solution of sodium hypochlorite (bleach) is both effective and economical for disinfecting cages, nest boxes, and ancillary equipment. Make the solution by adding an ounce of bleach to a quart of water. Place the solution in a spray bottle and spray it on the equipment to be sanitized.

Cages generally are sprayed after rabbits are sent to market and before the next occupants arrive. Spray feeders and watering devices at the same time. Clean and wash nest boxes before spraying with the solution. You can soak or rinse removable equipment in the hypochlorite solution. There are

no disadvantages to using this method of sanitation except that coccidial oocysts might not be killed.

Another disinfectant used by some rabbit breeders is lye water. One 13-ounce can of lye is enough to make 15 gallons of cleaning and disinfecting solution. For large ranches, it is advisable to buy the lye in the form of caustic soda. Each pound makes about 20 gallons of solution. Heating is advisable but not necessary. In addition to acting as a disinfectant, lye cuts grease and partly dissolves and penetrates fecal material.

Use of lye has some disadvantages. Concentrated lye is a poison and damages aluminum paints and clothing. The lye may be slightly irritating to the hands and face of the operator. Consequently, take precautions to avoid excessive exposure of the skin during the disinfecting process. Keep containers of lye tightly covered.

Some ranchers use steam under pressure to clean and disinfect pens and equipment. When using steam, first soak caked fecal material with water. Use of a good cleansing compound, followed by steam, cleans and disinfects satisfactorily.

Sunlight is a potent disinfectant if equipment is very clean and sufficient exposure time is allowed. A cement slab exposed to the direct rays of the sun is a good place to disinfect movable equipment.

Flaming or burning cages with a propane torch to remove hair does not sanitize the cage because the wires are not heated to a sufficient temperature to destroy the organisms. Be careful not to singe rabbits when burning hair. This procedure also is a fire hazard.

Practices to maintain health and prevent disease

Successful growers practice good sanitation and management, feed an adequate diet of simple ingredients, and give their animals plenty of fresh water.

It is important to inspect all animals in the herd each day. When you first notice sick rabbits, immediately try to

determine the cause. The following course of action is suggested:

1. Mark or note pens that contain sick animals.
2. Isolate sick animals. If possible, keep them in rooms or buildings separate from healthy rabbits.
3. Care for the sick animal *only after all other rabbits in the herd have been cared for* to prevent carrying infection from sick to healthy rabbits. Be sure to wash hands and disinfect boots after caring for sick animals. Clean and disinfect any equipment moved from an area where there are sick animals to the pens containing healthy animals.
4. If you cannot determine the cause of the trouble quickly, send a few typically sick

rabbits to a diagnostic laboratory or your local veterinarian.

5. Destroy all hopelessly sick animals and bury or burn all dead animals. Open disposal pits are not recommended.
6. Clean and disinfect all pens before placing new rabbits in them.

Bacterial diseases

Pasteurellosis

“Pasteurellosis” is the designation for all diseases associated with *Pasteurella multocida*. The disease manifestations are varied and include rhinitis (snuffles), pneumonia, pyometra, orchitis, otitis media, conjunctivitis, subcutaneous abscesses, and septicemia.

Rhinitis (snuffles)

The mucous membranes of the nasal sinuses become infected by bacteria from inspired air or by direct contact with infected animals or contaminated objects. The clinical disease is characterized by nasal sounds and by a catarrhal (mucus or pus) nasal discharge (*Figure 2*). The extent to which the infection spreads into the lower respiratory passages depends on the virulence (invasiveness) of the bacteria and the susceptibility of the animal. If the disease is confined to the upper passages, the first signs are sneezing followed by a nasal discharge. The inner aspects of the rabbit's forepaws may be caked with exudate because of attempts

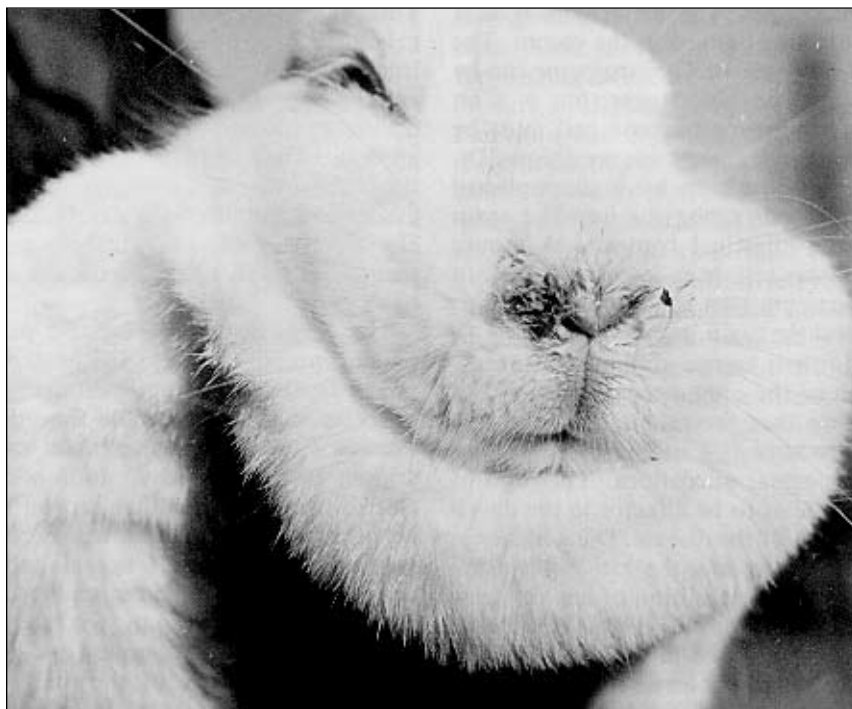


Figure 2.—Adult showing signs of snuffles. Note discharge from nose. (The large dewlap is normal on this animal.)

to wipe the exudate away from the nose.

Pasteurella bacteria often are found in the nasal sinuses of healthy-looking rabbits. Stress resulting from extremes of temperature, high humidity, high ammonia levels, travel, pregnancy, and lactation is a primary factor in the development of snuffles.

Treatment of snuffles has not proven to be economically effective in commercial rabbitries. By using broad-spectrum antibiotics such as oxytetracycline or chlortetracycline, the symptoms might be alleviated. However, the animal often remains a carrier of *P. multocida* and is able to infect offspring and caged neighbors.

Fluoroquinolones (e.g., Baytril) may be used in individual rabbits. Antibiotic combinations have been used to reduce symptoms in pet rabbits with some success. Antimicrobial

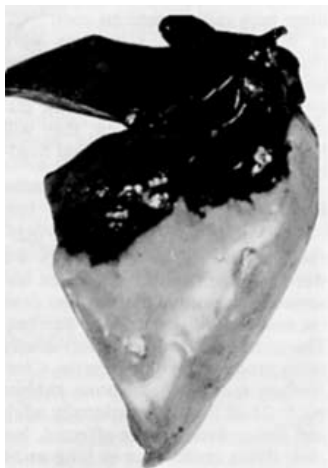

Figure 3.—Gross appearance of rabbit lungs, showing consolidation due to *Pasteurella* bacteria.

residues might remain in the treated rabbits' meat for days or weeks, making the meat unusable for human consumption. Penicillin use may cause fatal enterotoxemias.

If the nasal discharge regresses, take care not to stress the rabbit. It should not be used as a breeder. The next stress period (e.g., kindling, lactation, heat wave) very likely will cause the symptoms to reappear. Vaccines have not proven to be effective. The only effective method of control is strict culling. If a rabbit has a nasal discharge or matted paws or sneezes on 2 consecutive days, cull it from the herd. If you are not sure whether to cull a rabbit, "when in doubt, cull it out."

In addition to a strict culling program, good ventilation must be provided to control snuffles. There is a direct correlation between the level of ammonia in a rabbitry and the amount of respiratory disease. An effective manure removal system and 10–20 air changes per hour are necessary to reduce the ammonia to an acceptable level.

Pneumonia

Upper respiratory disease (snuffles) may spread to the lungs and cause pneumonia. Rabbit mortality surveys reveal pneumonia to be present in 25 percent of the animals examined; it is the greatest single cause of death in mature animals. Signs of pneumonia are depression, labored breathing,

bluish eye color in albinos, and a nasal discharge. The body temperature usually is above normal.

Gross lesions of the lungs appear as red consolidated areas, sunken purple areas, and abscesses. The consolidated lesions most often are in the anterior lobes of the lungs (*Figure 3*). A catarrhal exudate is found in the air passages. Abscesses appear with thin, fibrous capsules close to the surface of the lungs. Sometimes there are adhesions between the wall of the chest cavity and the lungs.

Pneumonia rarely is treated in rabbitries as it usually is a postmortem diagnosis. Broad-spectrum antibiotics have been used with some degree of success with pet and show rabbits.

Pyometra

"Pyometra" means pus in the uterus. The walls of the uterus usually are dilated, and the organ is filled with pus. Affected females will not produce and, therefore, are culled and often slaughtered. Pyometra results from the introduction of *Pasteurella* bacteria into the uterus during mating and may be traced to a single buck with a chronic infection of the testicles. It also can occur as a retrograde infection from the vagina.

Does that are nasal-positive for *P. multocida* often are vaginal-positive for the same bacteria, especially if the doe has a nasal discharge. The vagina is thought to be contaminated during the

normal practice of coprophagy (eating their own feces; see page 29) or during the kindling (birth) process.

Treatment of pyometra seldom is attempted because the disease usually is not noticed until the female is slaughtered. Successful treatment is unlikely. Pets sometimes can be saved by an ovariohysterectomy.

Orchitis

Orchitis is an infection of the testicles. The testicle becomes enlarged and usually contains an abscess. Pus can be seen when the testicle is cut open. Sometimes infection is limited to the membranes covering the penis, a condition called balanoposthitis.

Balanoposthitis appears as a reddening and swelling of the membrane covering the penis, and a white exudate (pus) is present on these membranes. As described above, the infection is transmitted to does by infected bucks during breeding.

Treatment seldom is attempted; however, balanoposthitis may be treated by applying antibiotic ointment containing penicillin or other suitable antibiotics to the penis.

Otitis media

Middle ear infection of one or both ears causes filling of the tympanic cavity with a purulent exudate. If the process spreads to the inner ear, the equilibrium of the animal is disturbed, and head tilt or wryneck results (*Figure 4*).



Figure 4.—Wryneck resulting from a middle and inner ear infection.

Although the *Pasteurella* organism is sensitive to certain antibiotics, treatment generally is not effective because of the isolated location of the infection.

Subcutaneous abscesses

Pasteurella may cause abscesses in many organs, but abscesses are especially evident when they occur in the subcutaneous tissue. These appear as soft swellings under the skin. Treatment consists of opening and draining the abscess and administration of systemic antibiotics.

Septicemia

This form of pasteurellosis usually is an overwhelming blood stream infection of short duration without clinical signs, resulting in death. Tissue changes are limited to a few hemorrhagic areas on the heart and pericardium, swelling of the spleen, and slight congestion of the upper digestive tract. The lack of clinical signs and short duration do not allow time for suitable treatment.

Enteritis

“Enteritis” is a group designation much like “pasteurellosis.” Any diarrheal-type disease that kills rabbits generally is placed in this grouping. In the past, the group designation often has been called “enteritis complex,” as many different symptoms were observed, but the one unifying factor was death as the final result of the syndrome. More recently, specific diseases have been described; they are discussed below.

Enterotoxemia

Enterotoxemia is an explosive diarrheal disease of young rabbits 4–8 weeks of age. Rabbits often are observed to be normal one day and dead the next with or without evidence of diarrhea. This acute death is due to a deadly toxin produced by the bacteria *Clostridium spiroforme*. Young rabbits die in 24–48 hours; occasionally adult and junior breeders are affected, and they may live as long as 96 hours. Penicillin used to treat rabbits may also cause the disease by altering the gut bacteria.

The typical lesions of enterotoxemia seen at necropsy are a fluid-filled intestine that is covered with petechial hemorrhages. The hemorrhage is most apt to be observed in the cecum. The causative agent, *C. spiroforme*, can be isolated on blood agar, but it is an anaerobic bacterium and must be grown under anaerobic conditions. Diagnosis



Figure 5.—This rabbit has mucoid enteropathy. Note feces on hind feet, rough fur coat, hunched posture, and squinty eyes.

of this disease is accomplished by demonstrating the iota-like toxin in the intestinal contents or by staining and microscopic examination for the distinctive bacteria in centrifuged cecal content. A mouse bioassay test or an intradermal test in guinea pig skin commonly is used to detect the toxin.

Little is known about the transmission of the organism, but it has been shown that rabbits do not have this organism as part of their normal microflora. The type of diet seems to be a factor in the development of the disease. Diets high in fiber reduce the incidence of the disease. The addition of hay or straw to a low-fiber diet is beneficial. Antibiotics used in the feed or water give temporary remission of symptoms, but the disease recurs once they are removed unless the diet has been changed.

Mucoid enteropathy

This uncommon enteric disease affects rabbits of any age and is a chronic type of diarrhea or constipation. Rabbits live for several days and sometimes several weeks with this disease. However, they will not eat and they sit hunched in the cage and grind their teeth as if in pain. They sometimes look bloated and often are crouched near the water supply (**Figure 5**).

The etiology of this disease is unknown, but one common finding in almost all cases is constipation. Impaction of the cecum and/or terminal part of the small intestine is observed at necropsy in about 75 percent of the cases. Along with the finding of a gelatinous-type of mucus in the colon, this leads to the diagnosis of mucoid enteropathy. Other lesions observed during a postmortem examination are generalized dehydration and excess water in the stomach. This latter finding causes a “splash” or “water bottle” sound when these animals are rocked to and fro close to one’s ear.

The impaction often can be palpated through the abdominal wall on young fryer rabbits, but treatment is not very successful. By the time the disease is recognized, the rabbit seldom can be saved. Rehydration with electrolytes sometimes is beneficial. The addition of excess salt to the ration occasionally helps stop an outbreak. Salt added to the

feed seems to increase water consumption and decrease the incidence of the disease. Adding salt to the drinking water or salt spools in the cage is not beneficial.

Tyzzler’s disease

Tyzzler’s disease was first described in Japanese waltzing mice, but since has been found in a variety of animals, including (uncommonly) rabbits. *Clostridium piliformes* is the causative organism.

Signs of the acute form seen in weanling animals are diarrhea, listlessness, lack of appetite, and dehydration, followed by death within 72 hours. Lesions include edema, hemorrhage, and necrosis in the wall of the cecum and focal necrosis in the liver and heart (**Figure 6**). The organisms are found in cells near necrotic areas, and the demonstration of typical bacteria within the cell is essential to diagnosis. Animals

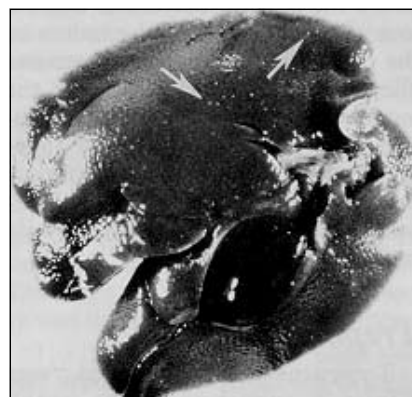

Figure 6.—Tyzzler’s disease. This rabbit died acutely with diarrhea. At autopsy, focal areas of cell death (arrows) were seen in the liver. Photograph courtesy of Academic Press and Co., New York.

surviving the acute stage might live to adulthood but fail to grow at a normal rate.

Transmission of Tyzzer's disease is by direct contact with fecal-contaminated feed and bedding. Some form of stress, such as overcrowding or extremes in temperature, is necessary for initiating the condition in nature.

Antibiotics reduce the effect of the disease in mice, but drugs seem to be of little value in rabbits. The best alternative is prevention through strict sanitation, especially daily thorough removal of fecal material from the cage floor. Because this seems to be a highly transmissible disease, the only way to treat severe outbreaks is to depopulate and repopulate with disease-free rabbits.

Coccidiosis

Coccidiosis is one of the enteric diseases. The etiologic agents are protozoan parasites that attack the liver or intestines. This disease is discussed under "Internal parasites," page 21.

Listeriosis

Listeria monocytogenes causes a rare septicemic infection in young rabbits, a meningo-encephalitis in adults, and metritis and fetal mortality in pregnant does. Pregnant females and does that recently have delivered young are most susceptible. The organisms are ingested or inhaled.

In septicemia, death can occur suddenly without previous illness. Generally the rabbit is depressed, weak, has a nasal discharge, and may have convulsions. Nervous system signs include incoordination, loss of equilibrium, and rolling movements. These signs may persist for several days or weeks, and complete recovery is rare. Sick pregnant animals have a purulent metritis, lose weight, and may abort. Survivors generally are useless for breeding because of uterine damage and pyometra (pus within the uterus).

The most consistent lesion at necropsy is liver necrosis. The lesions consist of a few pinpoint foci to almost complete studding of the liver. The mesenteric lymph nodes may be enlarged and reddened. In cases of metritis, the uterine wall is thickened, the mucous membrane may be covered with a grayish exudate, and the fetuses are decomposed or mummified. When infected fetuses are retained in the uterus, severe metritis develops.

Due to their tolerance by rabbits and their specific mode of action, antibiotics of the tetracycline group are the best drugs for treating listeriosis. In treating pregnant rabbits, antibiotics probably will not prevent fetal death, and females saved by antibiotics may be sterile as a result of the infection. The most effective prevention of losses is immediate isolation of diseased pregnant animals.

Necrobacillosis

Fusobacterium necrophorum, an anaerobic bacterium in farm animals, is considered a secondary invader rather than a primary cause of disease.

Lesions first appear on the lower lip, which becomes swollen, purplish, and painful to the touch. Later, small abscesses are seen that contain a thick, purulent material. These abscesses are enclosed in a tough, fibrous capsule, with little tendency to rupture and drain. The disease progresses to ulceration and necrosis of the skin and subcutaneous tissues in the face, head, and neck. When the liver and lungs become involved, the animal becomes emaciated and dies after several weeks.

Inadequate sanitation in the rabbitry, especially dirty cages, is prerequisite to this disease. When scratches, bite wounds, or skin wounds become contaminated with feces containing the etiologic agent, necrobacillosis is most likely to occur. The bacteria are sensitive to exposure to aerobic conditions and will not live long when exposed to air (oxygen).

When the disease is recognized and treated in its early stages, recovery is usual; when there is extensive ulceration and abscessation, death ensues. The organism is sensitive to some antibiotics, including metronidazole.

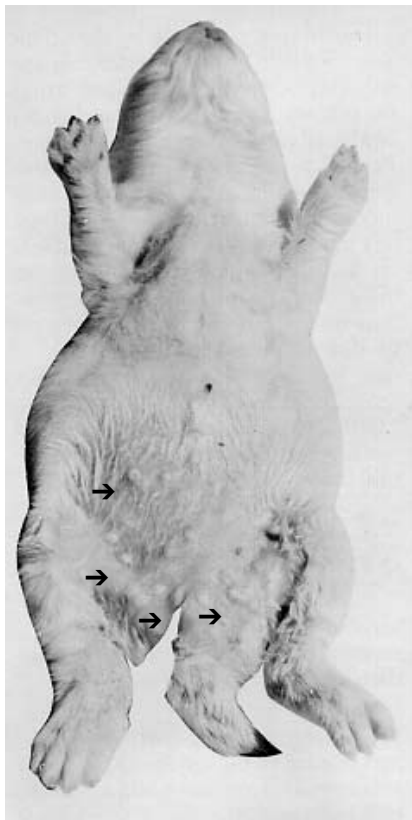


Figure 7.—Cutaneous abscesses on young rabbit caused by *Staphylococcus*.

Salmonellosis

Naturally occurring *Salmonella* infections are uncommon in domestic rabbits. *Salmonella* organisms are spread easily by fecal contamination, and a single infected animal can quickly infect a whole colony. Rabbits also can become infected by human caretakers, as *Salmonella* bacteria occur in humans as well.

Salmonellosis in rabbits generally is caused by *Salmonella typhimurium* or *S. enteritidis*, but *S. pullorum* also has been isolated. All members of the salmonellae group are aerobic,

gram-negative bacteria. In rabbits, the disease is characterized by septicemia and rapid death, with diarrhea and abortion commonly observed. When outbreaks occur, they often are explosive, with high morbidity and mortality. Mortality is highest in young rabbits and pregnant does. Bacteria are shed in the feces of carrier rabbits and clinically ill animals.

Infection usually takes place by the oral route, and signs appear after 3–6 days. The first signs are listlessness, ruffled hair coat, loss of appetite, and diarrhea. Later, the respiration rate increases, and body temperature may rise. In its acute form, the disease progresses rapidly to death. In the chronic form, there may be no signs of illness other than a transient diarrhea.

The most prominent lesions found at necropsy are in the liver, spleen, mesenteric lymph nodes, lungs, and intestine. Hemorrhagic and ulcerative changes are present in the intestine. The liver and spleen usually are enlarged and contain pinpoint, pale areas of necrosis. The lymph nodes may be soft, hemorrhagic, and enlarged. Surviving rabbits become carriers and may shed bacteria in their feces intermittently for a long time.

Streptomycin and other antibiotics have been used effectively against *Salmonella*. Animals treated with chlortetracycline respond to the medication, but may continue to excrete

organisms in their feces long after treatment. Pigeons, sparrows, and wild rodents have been shown to be reservoirs of *Salmonella*. Protect stored feed and bedding from these possible carriers.

Staphylococcosis

Staphylococcus aureus causes septicemic infections and abscesses in numerous organs, including the subcutaneous tissue, lungs, kidneys, and heart. This organism is known especially for causing infection in the mammary glands of nursing does. The breasts become swollen, hot, and may become bluish, accounting for the alternate name “blue-breast.”

Cutaneous lesions in young animals appear as small abscesses and later develop into firm caseous nodules (**Figure 7**). These abscesses usually are found on the lower abdomen, on the inner aspects of the forelegs, and on the lower jaw. Small, white nodules also may be found in the lungs and heart. The *Staphylococcus* organism also may cause bronchopneumonia. The lungs are consolidated, with numerous necrotic lesions. The bronchi and trachea may contain a mucopurulent exudate.

Bacteria enter the skin through broken or abraded areas following birth; transmission occurs from mother to young. Staphylococci live in the nasal passages of rabbits, and the close

contact associated with kindling and nursing offers opportunities for both direct contact and aerosol transmission.

Mastitis results from invasion of the milk glands by the disease-producing bacteria. The glands and teats become red and swollen and may advance to blue-black tissues, which are warm to the touch. The doe may refuse to nurse her young and generally loses her appetite. Young from does with mastitis should not be fostered to other nursing does because the disease might be transmitted to the foster doe. Mastitis also may result from abrasions to the teats or insufficient removal of milk when too few young are left with the doe or when the young are weaned too soon.

The septicemic form of staphylococcosis results in peracute death in young rabbits, primarily those still in the nest box. Death

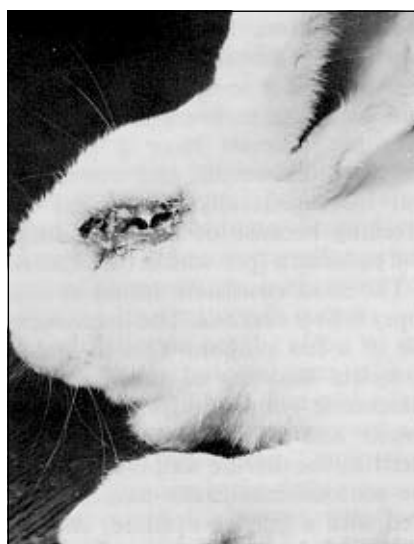

Figure 8.—*Conjunctivitis (weepy eye) caused by Staphylococcus infection.*

is so rapid that few if any lesions are observed. Occasionally, small, superficial pustules or abscesses (*Figure 7*) are seen on the skin of dead kits or littermates. Diagnosis usually depends on isolating *S. aureus* from the heart blood. The organism generally enters the young kit from ingested milk from mammary glands, or it may enter the body through abrasions or scratch wounds that become contaminated with *S. aureus*.

Staphylococci might be sensitive to several medications; however, some strains of the organism are resistant to one or more of these drugs. Laboratory tests may be necessary to determine which drugs should be used. Consult a veterinarian for current recommendations.

Mastitis

Mastitis most commonly is caused by *Staphylococcus aureus*; it is discussed under “Staphylococcosis,” page 12.

Conjunctivitis (weepy eye)

Conjunctivitis is a common malady of young rabbits raised under crowded conditions. Mature does and bucks occasionally are affected. Red, swollen eyes with a copious exudate are characteristic of this disease. In young rabbits, the eyelids often are stuck shut (*Figure 8*). It may affect only one eye or both. The bacteria most often isolated are *Staphylococcus aureus* and *Pasteurella multocida*. Conjunctivitis is treated by opening the eyelids, if stuck shut, cleaning the

surrounding tissues, flushing the eye with sterile saline or boric acid solution, and applying an ophthalmic ointment containing an antibiotic.

Conjunctivitis sometimes becomes a chronic problem in show rabbits, where the lacrimal secretions cause a loss of fur at the medial canthus of the eye. This condition sometimes is alleviated by intravenous antibiotic administration or by repeatedly flushing the lacrimal duct with an antibiotic solution. This procedure is best done with the rabbit under anesthesia and with a small-gauge cannula inserted into the opening of the delicate and tortuous lacrimal duct found on the lower eyelid near the medial canthus.

***Treponematosi* (vent disease)**

Treponematosi, sometimes called “vent disease,” spirochetosis, or rabbit syphilis, is caused by *Treponema cuniculi*. Other members of the genus include *T. pallidum*, the cause of human syphilis. Some of the early work on human syphilis was done with rabbits. After finding that rabbits had a natural spirochete, *T. cuniculi*, the validity of this early work in rabbits was questionable.

There is a great deal of confusion concerning the incidence of treponematosi in rabbits. Recent reports indicate it is much more common in commercial rabbitries than previously

believed. In fact, serological tests have demonstrated antibodies to *T. cuniculi* in a high percentage of adult rabbits despite the absence of observed lesions. Transmission of the organism originally was believed to be by sexual contact, and this method still is thought to be primary; however, vertical transmission from mother to offspring has been demonstrated. Vertical transmission accounts for the rabbits 6–8 weeks of age that show evidence of treponematosi s.

Lesions of treponematosi s may resemble those of injury, fungal infection, or ectoparasites. A correct diagnosis is important because the disease is transmitted primarily by breeding, and an isolated case can lead to an outbreak among the breeding stock. Exchange of infected bucks may spread the infection among colonies.

The first signs usually are small blisters around the external sex organs. Lesions involving the nose, mouth, and ears also occur in both sexes. The lesions are irregular in shape, tan-brown, and either edematous or dry and scaly. Sometimes weeping, coalescing vesicles are found. Facial and other lesions usually are secondary and the result of reinfection by contact with genital-anal lesions when the animal cleans itself. All lesions show many spirochetes by special microscopic (dark-field) examination.

Spirochetes also are found in regional lymph nodes, and they seem to survive in this tissue much longer than on the skin surface. Old lesions heal completely without scarring, but recovered rabbits are susceptible to later infection.

The spread of spirochetosis can be prevented by examining the genitals of both sexes before mating and by eliminating rabbits with lesions. The organism is sensitive to arsenicals and penicillin. Three subcutaneous injections of benzathene penicillin G-procaine penicillin G (42,000 IU/kilogram of body weight) are necessary to eradicate treponematosi s from a rabbit herd. Injections are given at weekly intervals, and *all* rabbits must be treated, regardless of the presence or absence of lesions. Penicillin, however, may cause fatal enterotoxemias in some rabbits.

Hutch burn

Hutch burn often is confused with rabbit syphilis. It is difficult to differentiate the two diseases without the use of a dark-field microscope. With this microscope, the spirochetes of treponematosi s are seen easily. Hutch burn affects the membranes of the anus and genital region. They become very red and chapped. The major cause is wet and dirty cage floors that come in contact with these membranes. The area soon becomes secondarily infected

with pathogenic bacteria and becomes very sore. Antibiotic salves and ointments hasten healing, but cleaning and drying the floors are essential to prevent recurrence.

Pseudotuberculosis

Pseudotuberculosis is an uncommon disease, but sometimes occurs in rabbitries with substandard sanitation. The causative agent is a bacterium, *Yersinia pseudotuberculosis*. Granulomatous nodules resembling tuberculosis are observed at necropsy throughout the intestine and occasionally in the parenchyma of the liver, lungs, or spleen. The organism, which seems to thrive in filthy conditions, enters the host through contaminated food or water. The disease is a chronic, debilitating condition with signs of poor appetite, depression, slowly developing emaciation, and eventual death.

Treatment of this disease seldom is effective. Prevention can be accomplished by good sanitation procedures, including disinfecting cages, nest boxes, and ancillary equipment. This disease has been diagnosed in humans and other animals; therefore, affected rabbits should be destroyed and not marketed.

Tularemia

Tularemia, sometimes called rabbit fever or deer fly fever, is an infectious disease of wild animals and humans that is caused by

Francisella tularensis. Tularemia can be carried by many wild and domestic animals, certain birds, deer flies, and ticks. It is an important malady of wild rabbits, but not of domestic ranch-raised rabbits.

Infected wild rabbits move sluggishly and are visibly sick. Yellow or white spots on the liver or spleen are common lesions. Diagnosis is made by bacterial cultures of suspect lesions. Domestic rabbits are susceptible to infection with this organism under laboratory conditions, but the disease has not been reported to occur naturally in commercial rabbitries. Tularemia might be transmitted from rabbit tissues to humans.

Viral diseases

Myxomatosis

The myxoma virus was isolated first in South America from diseased laboratory rabbits; the virus later was found to be a widespread natural infection in wild cottontail rabbits. In wild brush rabbits (*Sylvilagus bachmani*), it causes only mild tumors, which regress after several weeks; the disease is fatal only in the very young. In contrast, the disease can completely wipe out some susceptible populations of domestic rabbits.

Confirmed cases of myxomatosis follow the geographical distribution of the California brush rabbit, which is limited by the Pacific Ocean, the Columbia River in Oregon, the Cascade-

Sierra Nevada Mountains, and the tip of the peninsula of Baja California.

Transmission of the disease by mosquitoes led to the name "mosquito disease." Myxomatosis also is referred to as "big head disease" because of edema around the eyes, ears, lips, and nose in the early stages of infection.

Clinical signs include lusterless eyes with a purulent discharge and elevated body temperature. Edema of the ears causes them to become heavy and pendulous (*Figure 9*). As the disease progresses, edema of the head and anogenital region and a nasal discharge occur; death follows in 10–12 days. In survivors, widespread subcutaneous gelatinous tumors develop all over the body, including the eyelids.

Occasionally, acute outbreaks of myxomatosis occur and rabbits die in 24–48 hours. About the only clinical signs observed are a slight redness in the conjunctival membranes and an increased body temperature (about 108°F).

Rabbits dying from myxomatosis exhibit no characteristic gross visual changes by which the infection can be diagnosed definitely. Usually, there is congestion and consolidation of the lungs, and the spleen is enlarged, dark red, and pulpy. The cut surface of each edematous subcutaneous tissue is white, gelatinous, and glistening; when pressed, clear fluid exudes.



Figure 9.—This animal, affected with myxomatosis, shows heavy, pendulous ears and matted eyes.

Microscopic tissue examination or virus isolation is required for a definite diagnosis of myxomatosis. Large eosinophilic cytoplasmic inclusion bodies in the conjunctival membranes are observed microscopically. This finding, along with appropriate clinical signs, is evidence of myxomatosis.

The virus is spread by direct contact and by biting insects such as mosquitoes and fleas, which act as mechanical vectors. Control consists of prompt identification of the disease, destruction of infected animals, and reduction of mosquito populations by draining or spraying breeding areas. Screen enclosure of the entire rabbitry is an effective but costly solution. Antibiotics are not effective in treating sick animals. An attenuated vaccine is used for preventing myxomatosis in Europe, but the vaccine is not approved for use in the United States. The only effective measures available for use in California and Oregon are test and slaughter. Check rectal

temperature of suspect rabbits and immediately kill sick rabbits with a temperature greater than 104°F. Bury or burn the carcasses. This method, along with implementing a control program for flying insects, has been successful in stopping several major outbreaks in large rabbitries.

Rabbit pox

This rare disease can occur with or without manifestation of clinical disease. In either case, the lesions include lymphadenitis, papular nodules on the mucous membranes, and orchitis. Mortality is highest among the unweaned young and may reach 75 percent. Rabbit pox virus rarely is a cause of epizootics, but usually is very serious when it does occur. Vaccination with vaccinia virus confers immunity.

Fibroma

Rabbit fibroma virus was isolated from nodules beneath the skin of wild cottontail rabbits. These viral fibromas (firm growths) were transmitted to domestic rabbits. It once was believed that fibroma virus infected only wild cottontail rabbits; however, an outbreak has been reported in a commercial rabbitry.

In the cottontail rabbit, fibroma virus causes a benign tumor that regresses within a few weeks. Young domestic rabbits,

on the other hand, develop small, subcutaneous nodules to diffuse indurations involving muscle and tendon. The external genitalia become red and swollen. Death is frequent in unweaned young.

The cut surfaces of the nodules are pale and glistening and may have radiating white streaks. In young animals, the tumors are more widely spread over the body and often coalesce. There may be involvement of the kidneys, liver, intestinal tract, bone marrow, and mesentery.

The role of mosquitoes and other insects as vectors of rabbit fibroma virus has been established. Given the proper environment (such as an epizootic in wild cottontail rabbits) and an adequate mosquito population, this viral disease could result in significant economic loss of young domestic rabbits.

Herpes virus infection

Virus III or *Herpesvirus cuniculi* of rabbits exists as a latent infection in some stock lines of domestic rabbits. The virus does not produce a natural disease, nor are other species of animals susceptible. A virus with characteristics of the herpes group has been recovered from rabbits with respiratory signs. Its role as a pathogen has not been elucidated, but its association with respiratory disease may be important.

Another herpes virus that may be responsible for producing lymphoid tumors in cottontail rabbits recently has been isolated from these rabbits.

Rabbit papilloma

Rabbit papilloma virus has been identified as the causative agent of wartlike growth on the skin of cottontail rabbits (*Figure 10*). Domestic rabbits and jackrabbits are susceptible to experimental infection. The virus can be recovered from lesions on cottontail rabbits, but not from papillomas on domestic rabbits. Naturally occurring papillomatosis has been found in domestic rabbits in southern California, but the virus produces no evidence of a generalized illness.

The most common sites for papillomas are the ears and eyelids, and the growths vary in size and conformity. The growths are well keratinized, and the upper surfaces are irregular and often split. The lower portions of the growth are pinkish and fleshy to the touch. As the warts become older, they increase in size, become more cornified, and are hard to the touch. At this stage, they are easily scratched off by the rabbit or knocked off when handled. Papillomas removed in this way leave a free-bleeding surface, which heals without complications.

Rabbit papilloma virus probably is spread by free-flying insects such as mosquitoes; there

is no virus multiplication in insect tissue. Transmission of the virus from lesions of cottontail rabbits to domestic rabbits is most likely.

Oral papilloma

Wartlike growths in the mouth, especially on the lower surface of the tongue, are caused by a virus (one of the papovaviruses) different from the rabbit papilloma virus. Several spontaneous outbreaks of this disease have occurred, all in New York and Massachusetts. The growths on the tongue usually regress without specific treatment.

Viral enteric diseases

During the past decade, several viruses have been isolated from rabbits with diarrhea. Rotovirus, coronavirus, and adenovirus all have been incriminated in enteritis outbreaks. The clinical signs and pathology of the viral enteric diseases are very similar to those described under the section on bacterial diseases. It is not clear whether viruses act as the primary agent (with pathogenic bacteria as secondary invaders) or whether natural outbreaks of enteritis can be caused by these viral entities alone. A great deal of work currently is being done to answer the questions of viral pathogenicity and immunology.

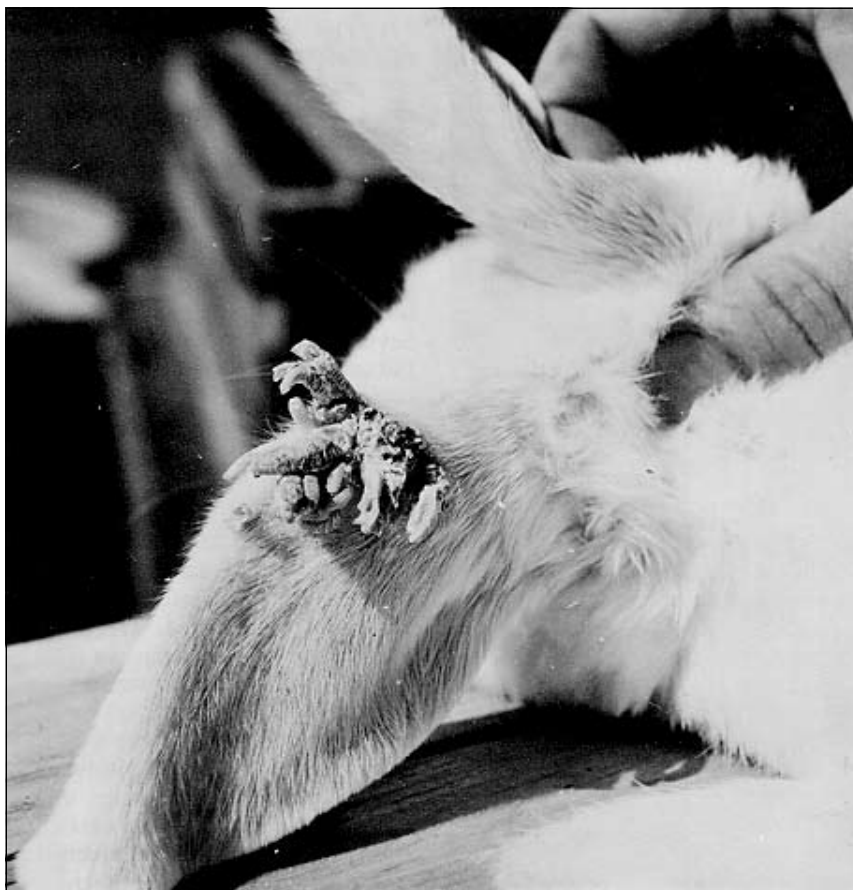

Figure 10.—Rabbit papilloma. Scaly growths on the ear were caused by papilloma virus.

Viral hemorrhagic disease

Viral hemorrhagic disease (VHD) first was reported in China in 1984. Since then, it has occurred in many European rabbit-raising countries, in Mexico, and in the United States. Rabbits with the disease show incoordination, convulsions, and evidence of severe pain. There usually is a bloody nasal discharge. Mortality rate of affected animals is very high.

Postmortem examination reveals hemorrhages throughout

the body organs such as the lungs, liver, heart, spleen, and mucous membranes. The liver is extremely swollen and brownish red.

Although the disease is very rare in the United States, animal health authorities keep a vigilant eye on imported rabbits and rabbit meat. The disease has escaped from quarantine centers in Australia and New Zealand and is decimating wild *Oryctolagus* rabbit populations in those countries.

Fungal diseases

Two main groups of fungi, *Trichophyton* and *Microsporum*, are found on rabbits and produce disease of the skin and fur under certain conditions. Not only can rabbits serve as reservoirs for human infection, but humans can transmit their fungus infection to rabbits. Because they produce a similar disease known as ringworm, the two organisms are discussed together in this section.

Fungus infections cause patchy areas of hair loss and thickened skin covered with

yellow, dry crusts (*Figure 11*). The hairs may be broken close to the skin surface and become matted. The name “ringworm” is suggested by the circular lesion that often develops from the outward growth of the fungi. Lesions usually are found on the nose, ears, eyelids, and feet. Their size varies, and in severe cases whole areas of the body may be involved. The infection usually is most severe in nursing young; single small lesions are more likely found in adults. Diagnosis of fungus infection depends on finding fungi in skin and hair scrapings and by

culture. Examination under Wood’s (ultraviolet) light may indicate *Microsporum* but not *Trichophyton*.

Infection of young rabbits probably occurs in the nest box. The nest-box material becomes contaminated with fungus from the adult, and minor skin abrasions allow the fungus to become established on the young. When nursing, the young are in direct contact with skin and fur around the doe’s teats, and the fungus is easily transferred to the mouth and nose regions of the infants. These same fungal organisms are found on dogs, cats, domestic livestock, and wild rodents around farm buildings.

Fungal infections must be differentiated from other types of skin problems, such as mite infestations, hair pulling, fight wounds, molting, and vitamin deficiencies. If ringworm is suspected after an evaluation of the lesions and clinical history, a skin scraping should be performed. The scraping should be taken from the periphery of the lesions, treated with 10 percent potassium hydroxide, and examined under a light microscope with reduced illumination. Fungal forms are identified easily by trained personnel.

When small numbers of animals are involved, a topical antifungal medication may be applied directly to affected areas. In larger outbreaks, an oral or



Figure 11.—Ringworm infection showing loss of fur and scaling of skin on the ears (arrow).

systemic medication is preferred. Griseofulvin, an antifungal drug, is the medication of choice. Each animal should receive 12 milligrams (mg) per pound of body weight per day for at least 15 days. Dissolve the drug in water and administer to the rabbit by gastric intubation. During treatment, add a fungicidal dust such as sulfur to the nest-box material.

Griseofulvin can be added to the feed at the rate of 370 mg per pound of feed and fed to all rabbits in the herd for a period of 2 weeks. While this is an extremely effective and easy way to treat ringworm, it presents a problem: The drug has never been cleared for use in rabbit feed in the United States and, therefore, cannot be added to the feed by a commercial feed company. This situation may be resolved in the near future.

Parasitic diseases

Rabbits are susceptible to a number of parasites, but only a few are of economic importance. The problems caused by all of these parasites are greatly influenced by methods of feeding, handling, and housing. If these are satisfactory, and if recently acquired animals are quarantined for a few days and checked for disease, most economically important parasitisms can be avoided.

Prevention and control

Prevention of parasite infection is far cheaper and preferable to treatment. The best preventive measures are sanitation, good housing, adequate food ration, and an understanding of potential parasite problems. Where good husbandry is the rule,

rabbits rarely are infested with parasites in significant numbers. Modern pens are constructed so that they can be kept clean and free from the infective forms of parasites. Proper cleaning of cages and use of good disinfectants, together with a good diet, are the keys to parasite control.

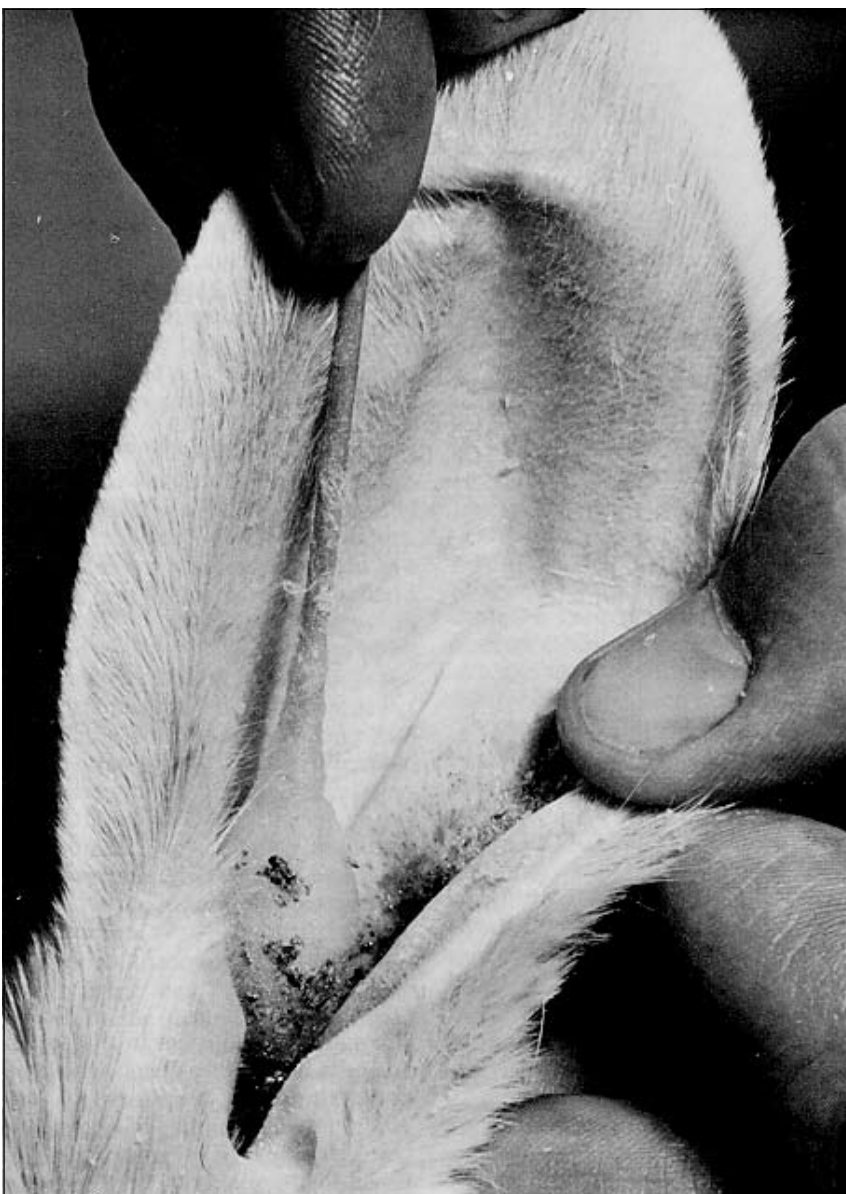

Figure 12.—Treating ear mites with a cotton swab soaked in medicated oil.

External parasites

Ear mites

Psoroptes cuniculi, the common ear mite of rabbits, causes ear mange or canker. This condition is a very common parasitic disease in commercial rabbitries.

The mites live in the ear canal and damage the skin lining this area. An exudate of brown, waxy material soon covers the inner ear (Figure 12). This dark encrustation consists of cellular debris, keratin, dried blood, and mites in varying stages of development.

The complete life cycle of the mite takes less than 3 weeks, and a severely infested ear can contain as many as 10,000 mites. In severe cases, the entire inner surface of the pinna may be involved, as well as the side of the head, the neck, and even the chin and shoulders. Severely affected rabbits lose flesh, fail to reproduce, and succumb to secondary infections.

Treatment of ear mite infestations requires a plan and perseverance. If ear mites are detected in one rabbit, they likely are in others in the herd also. To rid the herd of this bothersome parasite, treat all rabbits in the herd regardless of whether ear mites are detected. Treating just the one rabbit will result in continually treating one or two rabbits a week.

Most mineral-oil-based ear mite medications containing a parasiticide are effective, as are treatments using ivermectin.

Place oil-based preparations (two or three drops) in both ears of all adult and potential replacement rabbits in the herd. Massaging the base of the ear after administering the medication distributes the drug throughout the surface of the ear canal. If rabbits are severely infected and have a large amount of debris in the ear canal, soften the debris with mineral oil and remove it with cotton-tipped applicators and tweezers before drug application. Treat rabbits with noticeable ear mite infestations every day for three treatments, every other day for three treatments, and then weekly for three treatments. Treat rabbits without noticeable ear mites monthly for three treatments. Ivermectin is given two or three times at 2-week intervals.

Fur mites

Cheyletiella parasitovorax and *Listrophus gibbus* are two common mites inhabiting the skin of rabbits. In healthy, well-fed rabbits these mites seldom cause a problem and rarely are noticed. If a rabbit becomes sick or is underfed, alopecia, sores, or scabs may develop in the neck or dorsal trunk areas. Intense itching may occur, which causes constant scratching with the hind legs and the consequent loss of hair and injury to the skin.

Diagnosis of fur mites is best accomplished by scraping the skin of the affected area with a scalpel blade dipped in mineral oil. The resulting debris then is

examined microscopically for evidence of mites and eggs. To treat fur mites in a few rabbits, apply a cat flea powder at weekly intervals for several treatments. If a fur mite infestation becomes a herd problem, treat with injections of ivermectin or dip rabbits (wear gloves) in a 0.5 percent malathion solution at 10-day intervals for two treatments.

Cuterebrid flies

Larvae of *Cuterebra* flies are common subcutaneous parasites of wild rabbits but infrequent parasites of domestic rabbits. The adult fly appears wherever populations of wild rabbits exist. Rabbits are infected when the fly deposits eggs on the fur. Grub worms hatch from these eggs and burrow into the skin to form warbles. The larvae grow under the skin and may get as long as three-quarters of an inch (Figure 13). When full-grown, the grubs leave the skin, drop to the ground, and develop into adult flies. The warbles cause

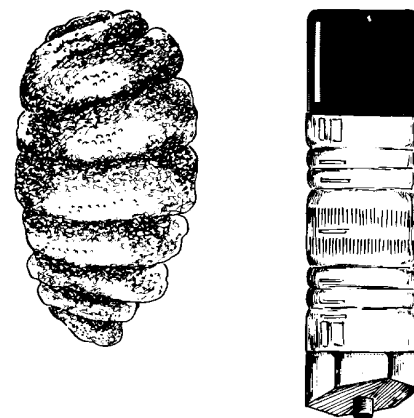


Figure 13.—*Cuterebra* larva. An eraser on a pencil is shown for size comparison.

little trouble when they are found in small numbers. The larvae can be removed by enlarging the opening in the skin and drawing them out gently with tweezers. Paint the wound with an antiseptic.

Fleas and ticks

Rabbits are not commonly infested with fleas; however, the rabbit flea, *Spilopsyllus cuniculi*, and the dog and cat fleas, *Ctenocephalides canis* and *C. felis*, occasionally have been reported on rabbits. There are four stages in the life cycle of these fleas—egg, larva, pupa, and adult. The eggs are deposited on bedding and in cracks of nest boxes and develop into larvae in a short time. These

larvae then form pupae from which adult fleas emerge.

Control is aimed at killing the adults on the host and the immature forms in the nest box. To destroy adult fleas, dust rabbits with a commercial preparation of pyrethrum or rotenone. Repeat several times during a 2-week period. Control immature forms by burning old nest-box litter and scrubbing nest boxes with hot water and household bleach. More modern drugs for preventing and treating ectoparasitism in dogs and cats may be used in rabbits also. Consult a veterinarian.

The rabbit tick, *Haemaphysalis leporispalustris*, is a common

parasite of wild rabbits, but rarely is found on domestic rabbits because their housing is not compatible with the life cycle of the tick; however, this tick is one of the reservoirs of tularemia, a serious human disease. Take care to ensure that wild rabbits are not allowed access to areas in which domestic rabbits are being raised.

Internal parasites

Coccidiosis

Coccidiosis is a prevalent parasitic disease of domestic rabbits. It is caused by a microscopic protozoal parasite that invades the intestine or liver. In these locations, the parasite multiplies extensively and then sheds eggs in the feces. At least four species or types of coccidia live in the intestine, and one species grows in the liver.

Not all species of coccidia are equally harmful, and rabbits tolerate moderate numbers of some without displaying illness. The most dangerous of the intestinal forms are *Eimeria magna*, *E. media*, *E. perforans*, and *E. irresidua*. These produce diarrhea, poor appetite, weight loss, and sometimes death. *E. irresidua* evokes the most severe tissue damage. In some cases, patches of epithelium die and slough away from the intestinal wall.

The diagnosis of coccidiosis depends on the finding of the oocysts (eggs) in the feces or intestinal contents. However,

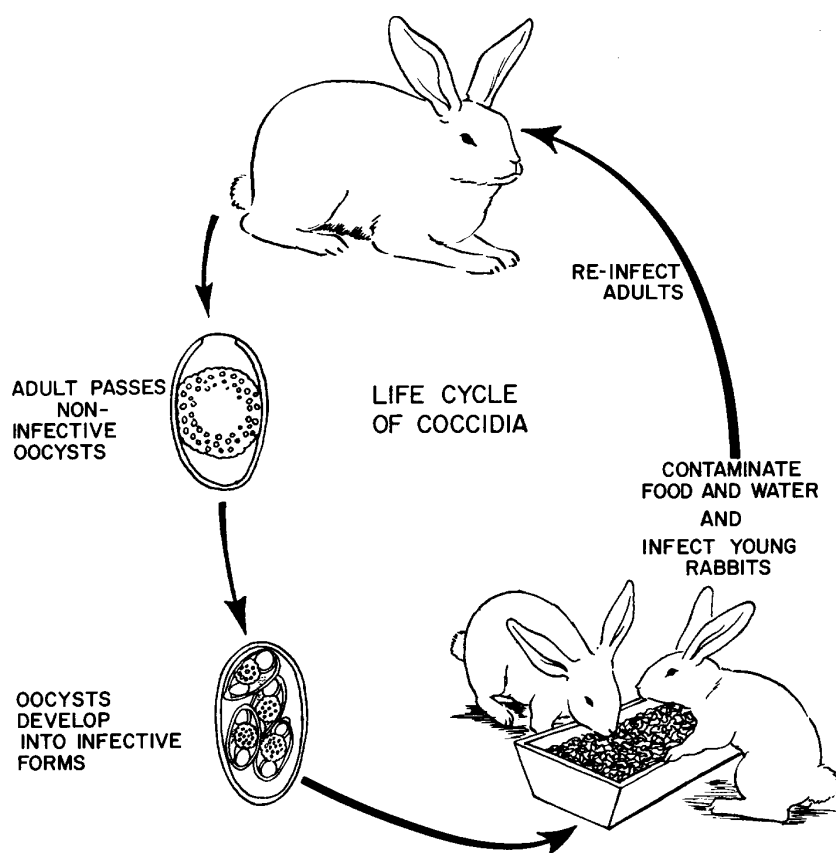


Figure 14.—Life cycle of coccidia.

experience is needed to judge whether sufficient numbers of parasites are present to account for the disease signs, because other disorders may produce similar signs.

Control of intestinal coccidiosis depends largely on management practices that minimize the danger of fecal contamination of feed, water, and hutch floors. Wire-bottom floors greatly reduce the hazard presented by solid floors or slots. However, brush wire floors daily with a wire brush to ensure that fecal material falls through the wires. This breaks the life cycle of the organism. Design feeders so that fecal contamination is held to a minimum. An automatic water system is recommended. Oocysts passed out in the feces require moisture and warmth to sporulate and become infective (*Figure 14*). Dry wire floors and automatic water systems hinder sporulation of the parasite. Oocytes persist in the environment and are difficult to kill with most common sanitizing agents.

Treatment has only a temporary effect during the early stages of intestinal coccidiosis, but it may be useful in controlling outbreaks. When indicated, a ration containing 0.025 percent sulfaquinoxaline may be fed for 2 to 3 weeks to reduce the numbers of parasites to a level where control can be accomplished by proper management. Intestinal coccidia develop a tolerance to the drug if used continuously, so

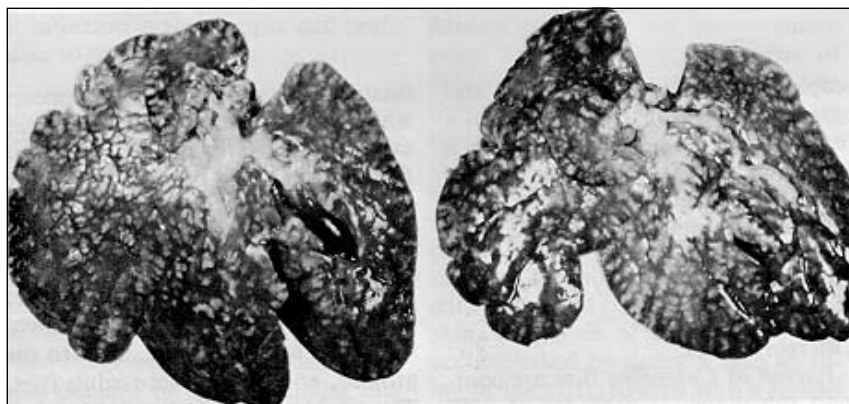


Figure 15.—Livers of rabbits affected with hepatic coccidiosis.

treatment is not suggested unless clinical disease appears. Meat rabbits so treated must be held for at least 10 days following cessation of treatment to allow breakdown of antimicrobial residue in muscle tissue.

Eimeria stiedae, the one species that multiplies in the liver, is considered to be the most pathogenic coccidium of rabbits. Like the other forms, it enters the intestinal wall, but it migrates to the bile ducts, where it reproduces. Infections lasting more than 16 days can be recognized by white circular nodules on the liver (*Figure 15*). The parasite multiplies in the epithelial cells of the bile ducts, which become thickened and tortuous and contain a vast number of oocysts. In the early stages of infection, there are no unusual symptoms. Then appetite decreases, a potbelly develops, and death sometimes follows. In moderate infections, there is no mortality, but disfigurement of the liver makes it unmarketable; hence this type of coccidiosis always is of economic significance.

Liver coccidiosis is acquired in the same manner as intestinal coccidiosis. The control measures also are similar; however, liver coccidiosis can be controlled more easily by proper management. When the disease does occur, feed containing 0.025 percent sulfaquinoxaline is an effective treatment. It can be fed at this level for 3 weeks; use it only until management control measures can be introduced.

Encephalitozoonosis

Encephalitozoon cuniculi (a protozoan parasite) is the cause of a mild but long-standing disease in rabbits. The condition was first described as a chronic encephalitis, sometimes with clinical signs such as a spontaneous paralytic disease. A chronic nephritis caused by the parasite was overlooked for many years, but current studies indicate that many apparently healthy animals have kidney lesions related to this infection. These lesions vary from cortical scarring with multiple small, indented, gray areas on the surface to

a granulomatous nephritis (*Figure 16*). The scars extend from the cortical surface to the medulla.

Encephalitozoonosis is a contagious, colony infection. The organisms are passed in the urine and transmitted when there is urinary contamination of feed or water. A diseased doe also can transmit the disease to unborn rabbits in the uterus. The disease can be controlled by providing good sanitation and preventing contamination of food and water by urine. No treatment is available.

Diagnosis of encephalitozoonosis in a rabbit herd is difficult. It usually is done at necropsy by observing histopathologic lesions typical of the disease. Recently, several diagnostic tests have been developed that will help with the diagnosis in live rabbits. An *Encephalitozoon* infection can be detected by an indirect fluorescent antibody test, a skin test, or by a carbon immunoassay utilizing India ink. These tests may be helpful in antemortem diagnosis and

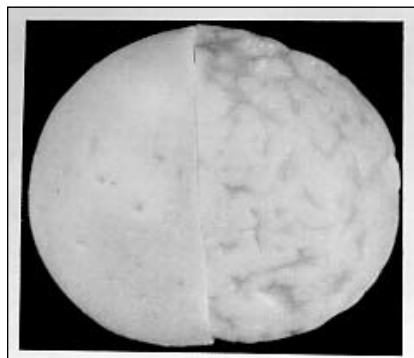


Figure 16.—Halves of kidneys from two rabbits showing pitting of the surface caused by *Encephalitozoon cuniculi* (right).

also in screening rabbits to point out possible carriers or infected animals.

Toxoplasmosis

Toxoplasmosis is an uncommon protozoal disease of rabbits caused by *Toxoplasma gondii*. The disease has been reported worldwide in both domestic and wild rabbits. The disease probably is more common than reported, as antibody tests on rabbit herds have shown that as many as 50 percent of clinically normal rabbits have been exposed.

There are two forms of the disease. In the acute form, the rabbit develops anorexia, fever, lethargy, and (in a few days) central nervous symptoms ranging from ataxia or posterior paralysis to generalized convulsions. Death usually occurs about a week after symptoms are first noted. In the chronic form, the disease occurs over a much longer period of time. In fact, it may be latent, with onset stimulated by stress. With the chronic form, either no symptoms are observed or there is a progressive emaciation that might end in posterior paralysis and death.

Transmission of the disease may occur in two ways. Cats can shed the parasite in their stool and thereby contaminate stored rabbit feed; then the contaminated feed is ingested by rabbits. The parasite also can be transmitted through the placenta of a pregnant doe to her offspring.

At necropsy, the lesions of this disease vary. In the acute form, there is extensive necrosis of the lymph nodes, liver, spleen, and lungs. This generally is observed histologically, but grossly the organs may be swollen, and necrotic small white foci may be observed. The parasitic organism often is found with the aid of a microscope in these necrotic foci. In the chronic form, there may be microscopic lesions but no apparent gross lesions, and organisms often are confined to the central nervous system.

Diagnosis of toxoplasmosis generally is accomplished at necropsy by observation of histologic lesions and organisms. Various serological tests also might be useful. Treatment in most cases is not practical, and the emphasis should be on prevention. Cats, the primary carrier of this organism, should be kept out of rabbitries or at least away from feed storage areas. Take precautions to ensure that feed and water are not contaminated with toxoplasma oocysts.

Roundworms

Only one roundworm presents a problem in domestic rabbits. Several more have been reported in wild rabbits, but these rarely occur in domestic rabbits. The pinworm, *Passalurus ambiguus*, is a very common parasite of domestic rabbits, but it does not affect other animals or people.

These pinworms are glistening white, and $\frac{1}{2}$ inch long. They often are seen on the surface of freshly passed feces or through the wall of the cecum when rabbits are slaughtered. Ordinarily, pinworms do little harm. As the mature worms become inactive, they are passed out of the cecum as fecal pellets are formed. These parasites are spread from animal to animal by ingesting feed and water contaminated by the droppings of infected animals. Management methods used to control coccidiosis are effective against pinworms. When treatment is necessary, piperazine citrate is effective when administered at 100 mg/100 milliliters (ml) drinking water for 1 day. Reinfection occurs readily.

Tapeworms

Tapeworms occur in rabbits as adults in the intestine and as larval forms in the liver and abdominal cavity. The adult forms are very rare in hutch-raised rabbits, but larval forms occasionally are observed.

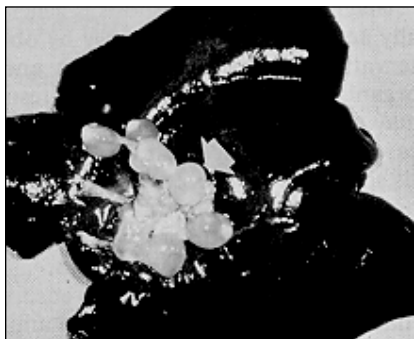


Figure 17.—Rabbit liver with several cysticerci attached (arrow).

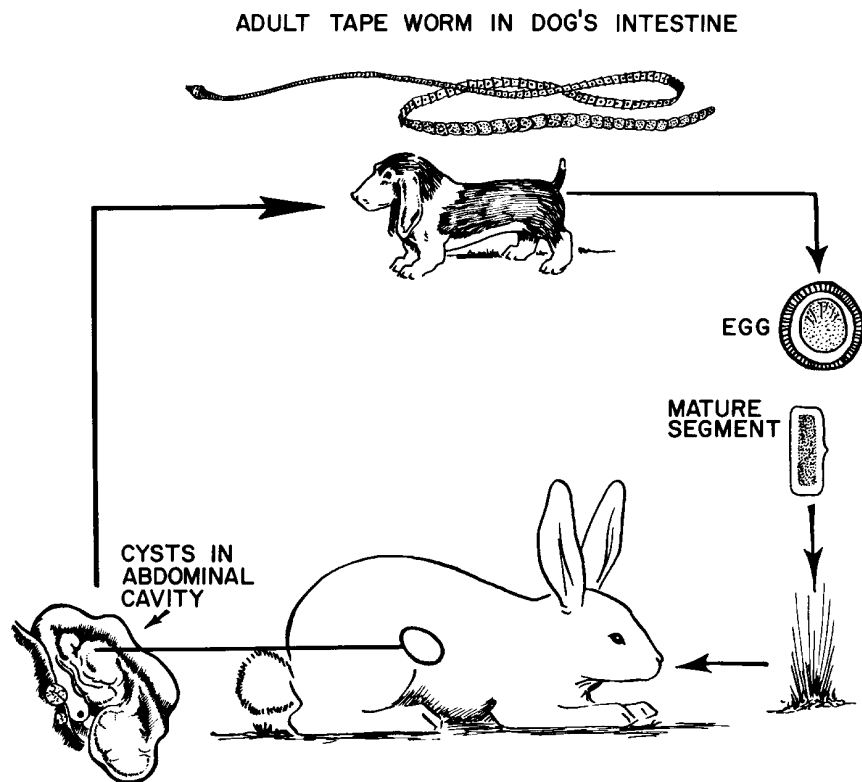


Figure 18.—Life cycle of the dog tapeworm.

The rabbit tapeworm *Citotona variabilis* is uncommon in domestic rabbits. It is flat, ribbon-shaped, and made up of numerous segments. It has a head with four suckers with which the worm attaches to the lining of the intestine. Rabbits harboring a few tapeworms show no signs of the disease. When many tapeworms are present, diarrhea and emaciation might occur. Control is readily accomplished by good sanitation.

The larval forms of tapeworm most often found are those of *Taenia pisiformis*. They are found in the abdominal cavity and in the liver. Rabbits acquire these tapeworms by ingesting contaminated feed and water containing

tapeworm segments and eggs from the feces of dogs.

The young larvae then are released from the eggs, penetrate the digestive tract, and migrate to the liver. They migrate within the liver, leaving white streaks behind, then leave the liver and enter the abdominal cavity. They form small, fluid-filled cysts (cysticerci), which may be attached to the membranes holding the intestinal tract or may exist free in the abdominal cavity (Figure 17). Each cyst contains an embryonic tapeworm that, when consumed by a dog, will develop into a mature tapeworm.

By excluding dogs from the rabbitry, transmission of tapeworm eggs can be prevented (Figure 18). Dogs kept on

premises where rabbits are raised should not be allowed to eat any part of a raw rabbit carcass. Treatment for larval stages in the rabbit is not practical, so control must be accomplished by management.

Nutritional diseases

Pregnancy toxemia

Also known as “ketosis,” this disease is a toxemia of pregnancy that is most common in first-litter females. Signs of ketosis are dullness of the eyes, sluggishness, respiratory distress, prostration, and death after 1 to 4 days. The disease occurs in the last week of pregnancy and is much more prevalent in obese animals. The probable major cause is starvation with subsequent metabolic effects on the doe and young. For some reason, there is a loss of appetite and failure to eat. This may be the result of minor digestive upset (hairballs in the stomach are common), an abrupt reduction in exercise, or a ration containing too little digestible carbohydrate. When carbohydrate energy declines, body fat is mobilized for energy, and ketone bodies are produced and enter the bloodstream. The liver becomes fatty and appears brown and soft.

Birth of the litter or abortion is apt to be curative if either occurs shortly after the onset of signs. Injections of fluids

containing glucose may reverse the breakdown of body fats and halt production of ketones. Junior does should not be too fat when bred for the first litter.

Vitamin A deficiency

Low-grade vitamin A deficiency adversely affects the reproductive performance of females, often before other signs are noted. Premature degeneration of the ovum and reduced numbers of fertilized ova result. Resorption of the fetus or abortion during late gestation also is noted.

Rabbits born to females fed a diet deficient in vitamin A may be hydrocephalic at birth. Hydrocephalus, or “water on the brain,” is characterized by distention of the portion of the skull that covers the brain. Cases may not be apparent because the young die soon after birth or are born dead. Animals that live show signs of nervous system involvement. Wryneck, loss of equilibrium, and incoordination persist for several days or weeks. Impaired coordination may prevent animals from eating, and eventually they die of starvation. Enlargement of the head is caused by increased pressure within the brain. On cut section, the ventricles (cavities) of the brain are greatly enlarged and filled with a clear, colorless fluid.

Hydrocephalus is caused by low maternal blood levels of vitamin A throughout the

gestation period. When maternal blood levels fall below 20 micrograms (ug) per 100 ml serum, hydrocephalus appears in a large percentage of the young. Commercial diets, in general, supply adequate levels of vitamin A; however, the vitamin does deteriorate after prolonged storage of alfalfa hay.

It has been shown by workers at Oregon State University’s Rabbit Research Center that *excess levels* of vitamin A can cause the same signs and symptoms as *deficiency* of the vitamin. Low fertility, abortions, resorption, and hydrocephalus were seen in does given excessive vitamin A in the diet. Excess vitamin A may be a problem if a vitamin premix is added to rabbit diets containing high levels of alfalfa.

Vitamin E deficiency

Infant mortality, characterized by death of entire litters at 3 to 10 days of age without clinical signs prior to death, has been associated with vitamin E deficiency. Affected infants do not reveal any gross lesions of diagnostic significance. Producing females become less fertile as the deficiency progresses. The problem can be treated because adequate supplementation of vitamin E will stop infant mortality and correct infertility. Alfalfa hay is a suitable source of vitamin E in commercial rations, and 8–9 mg/100 grams (g) feed is adequate.

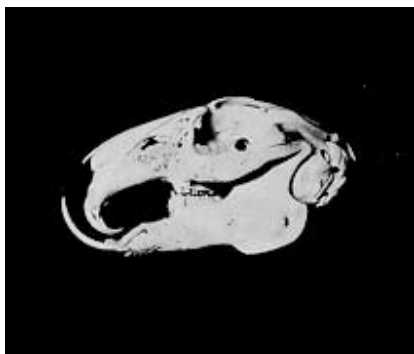

Figure 19.—Malocclusion.

Hereditary diseases

Glaucoma

Glaucoma (buphthalmia) occurs in both laboratory and commercial rabbit colonies. This condition is of interest to ophthalmologists because of its similarity to congenital glaucoma in humans, and rabbits may serve as a useful animal model.

Glaucoma appears first as a light bluish cloudiness on the cornea. One or both eyes may be affected. Progressive opacity follows, and protrusion of the eyeball becomes noticeable. Corneal opacity may lead to blindness.

Glaucoma probably is the result of an abnormal drainage mechanism and the inability to maintain normal fluid relationships in the eye. It is a semilethal defect that is transmitted as a recessive trait.

Malocclusion

Malocclusion and tooth overgrowth, or “wolf teeth,” have long been recognized as common

problems in rabbit colonies. The dental formula of the rabbit is: incisors 2/1, canines 0/0, premolars 3/2, and molars 3/3. Constant chewing and gnawing keep the teeth ground down to proper length and size. When the lower jaw is shorter or longer than the upper jaw or teeth are damaged, malocclusion of the incisors might result in overgrowth (Figure 19). The cheek teeth (premolars and molars) meet and grind evenly in normal animals. These teeth continue to grow and depend on constant grinding against opposing teeth to maintain their shape. If there is a malposition of the jaw, broken teeth, or malformation, overgrowth will occur in the cheek teeth similar to that which occurs in the incisors.

Signs of malocclusion are gradual loss of appetite and weight. Both sides of the mouth may become stained with saliva. Animals become progressively listless, dehydrated, and unable to chew properly. Complications are abscessed teeth, growth of teeth into the upper jaw, and death from starvation.

Malocclusion of the incisors can be corrected temporarily by cutting back the teeth so the animals can eat and attain good condition before slaughter.

However, never use these animals as breeding stock because many types of malocclusion are inherited. Young rabbits occasionally pull on cage wires or feeders with their teeth and cause

misalignment, which also results in malocclusion. This type of malocclusion is difficult to differentiate from inherited malocclusion. Therefore, the best solution is to regard all malocclusion as inherited. The recessive malocclusion genes can be eliminated from a breeding herd by selective breeding.

Splay leg and ataxia

Splay leg in rabbits is due to one or more recessive genetic factors. The condition might be similar to the hip dysplasia found in certain breeds of dogs.

The disease is characterized by an inability to put weight on one or both hind legs, and might even involve all four limbs. The limbs are twisted so the animals have a double-jointed posture. Affected animals are not paralyzed. They eat normally, seem to be well, and move by wriggling along on their belly and chest. The pathologic effects are limited to the hip and shoulder.

Ataxia (muscle incoordination) resembles splay leg in some respects. It is, however, a lethal recessive genetic factor. The disease usually appears when the animal is 2 to 3 months of age and runs its course in 30 days. In ataxia, the nervous system is involved, and at first the animal might not be able to use its hind legs effectively. Later the animal cannot move, and its body temperature drops below normal until death ensues.

Miscellaneous

Cannibalism

Most cases of cannibalism are the result of a diet that is inadequate in either quality or quantity, injury or abnormality in a baby rabbit, or disturbance of the doe following kindling. Proper feeding and seclusion at kindling usually prevent the tendency. A valuable doe that destroys her first litter should be given another chance. If she continues to kill young, she should be culled from the breeding population.

Heat prostration

Heat prostration results from prolonged exposure to excessive heat. Losses may be high in females due to kindle or in baby rabbits if nest boxes are poorly ventilated. Just before dying, animals breathe rapidly and become comatose.

Provide relief to adult animals suffering from the heat by spraying them with water or placing a wet burlap feed sack on the cage floor for them to rest on. Remove some bedding and fur from nest boxes to improve circulation of air around kits.

In locations subject to high temperatures, overhead water sprinklers help to reduce the air's temperature by evaporation. Aluminum-roofed sheds reflect the heat, and burlap sacks soaked in water can be hung from the edges of the roofs to shade and cool the air.

Draining water lines or crocks and refilling with cold water for immediate consumption aid in reducing rabbits' body temperature. It is also helpful to change breeding schedules to reduce the number of late-pregnancy does in the hottest part of the summer.

Broken back

This condition is characterized by sudden paralysis with no apparent cause. Paralysis extends posterior from the middle of the back and may be complete or partial (paresis). The animal moves with its front legs and drags the hindquarters. The urinary bladder may become greatly

distended. Paralyzed animals have a displaced or slipped vertebra. Malposition of the vertebra compresses and damages the spinal cord with resulting paralysis. Injury to the vertebra may be caused by improper handling, use of a tattoo box too short for the animal, or injury. Many injuries occur at night when predator animals invade the rabbitry. In an effort to evade the predator and protect the young, the adult "stamps" firmly with its hind feet. As a result, a vertebra becomes displaced, and the spinal cord is damaged.

Adult rabbits have been observed to cause a luxation of the vertebrae by sudden

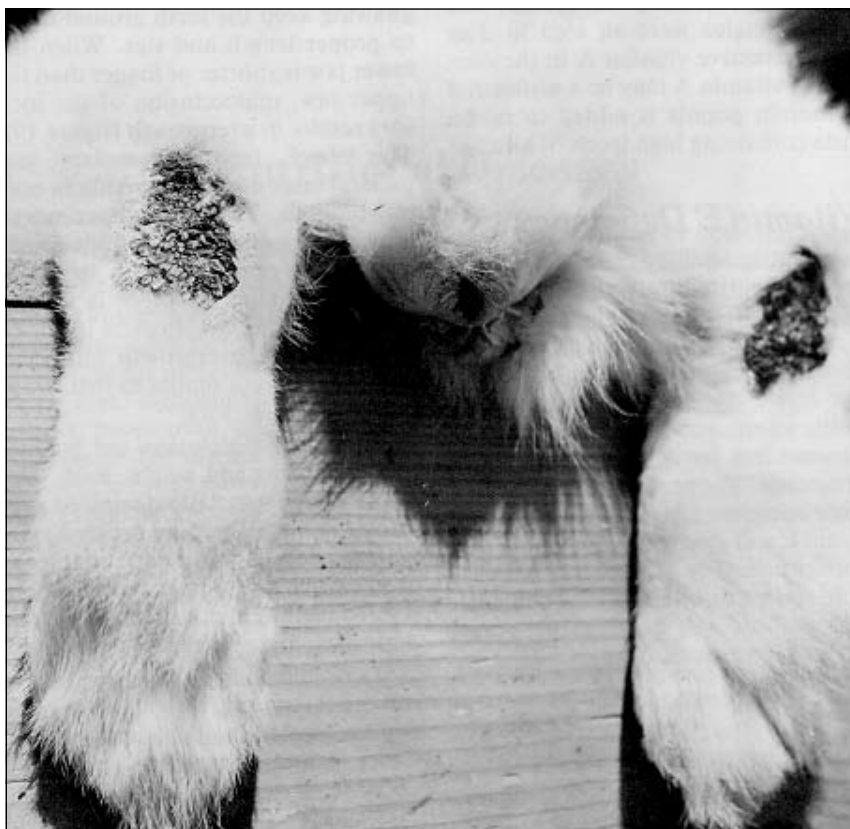


Figure 20.—Sore hocks.

movements when startled by a person entering the rabbitry. This is especially true if background noise (such as a radio) is not available and the person is a stranger.

If a rabbit is completely paralyzed, it generally is killed. However, some success has been observed in does with paresis (some motor function or sensory capability) by putting the rabbit in a small cage for 30 to 60 days. The smaller cage limits the rabbit's activity and allows time for repair of the injury.

Sore hocks

Sore hocks are inflamed bare spots, devoid of fur, found on the bottom surface of the hind legs (*Figure 20*). In severely affected cases, secondary infections with *Staphylococcus* occur. Both front and hind feet might become involved. As the hocks of the hind feet become painful, the animal throws more weight to the front feet, adding stress to the front feet and causing them to become affected. Wet, dirty hutch floors and the irritating action of urine salts are predisposing factors. The breed also is a factor in the development of sore hocks; the disease is seen more often in large breeds than in smaller breeds. Rex rabbits are prone to the disease because of thin foot pads.

Treatment of sore hocks often is nonproductive. Even if treatment is successful, the lesion almost always returns, and the

animal seldom is useful as a breeder. The best method of treatment is prevention. Prevention is accomplished in three ways. First, cull all affected breeders from the breeding herd because of a genetic predilection for sore hocks (thickness of the foot pad). Second, clean cage floors daily and never allow manure to hang on cage floors. Third, inspect cage floors frequently for rough spots or rusty areas.

Tumors

Spontaneous tumors in rabbits rarely are reported because the animals are slaughtered before they reach the age at which tumors are most apt to occur. With the increasing use of rabbits as laboratory animals, interest in these growths can be expected. Tumors have been observed in the uterus, kidneys, blood, lymph nodes, bones, testicles, skin, and other organs. Adenocarcinomas of the uteri are not uncommon in does over 2 years of age. Usually they are multiple and occur in both uteri. Most cases of lymphosarcoma (tumors of cells from lymph nodes) occur in mature females. Neoplastic cells are found in numerous body organs, but the most outstanding lesions are in the kidneys. Another tumor originates from embryonic cells in the kidneys (embryonal nephroma) and is observed with some frequency in domestic rabbits.

Fur eating and hairballs

Several rabbits in a hutch may eat body fur, eyelashes, and whiskers. Single rabbits eat fur on their sides, back, and rump. The cause generally is a deficiency of dietary fiber and gastric atony. Diets high in cereal grains and low in alfalfa often have a low fiber content. Because the rabbit's digestive system is designed for handling large amounts of fiber, a deficiency in the diet causes the animal to seek another source of fiber, and hair chewing begins. Increasing fiber in the diet almost always eliminates the problem. Overcrowding in a cage also can cause hair loss, mainly from fighting.

Rabbits also eat small amounts of hair by licking or grooming themselves. The hair may accumulate in the stomach and form hairballs. These usually cause no disease, but they may obstruct the stomach. When obstruction occurs, the rabbit quits eating, loses weight, and may die.

If a hairball is suspected, parenteral fluids, gastric muscle stimulation, massage of the (delicate) stomach, and, perhaps, administration of 10 ml of pineapple juice by stomach tube or medicine dropper 3 days in a row might help. An enzyme in the juice might help break up the hairball and allow it to pass through the digestive system. Surgery might be needed in some cases.

Coprophagy

Rabbits take soft fecal pellets from the vent and swallow them intact. This is a natural physiological process for rabbits and should not be misinterpreted as a nutritional condition or depraved appetite. Coprophagy is practiced at night by tame rabbits and during the day by wild rabbits in their burrows. Fermentation of the feces in the large intestine supplies an abundance of certain B vitamins to the fecal pellets, probably improves the quality of the protein in the soft pellets, and improves fiber breakdown by bacterial action. By permitting a second passage of food through the digestive tract, the rabbit gains additional nutritive value from the food.

Yellow fat

Yellow body fat is an inherited condition in rabbits. It is included here only to prevent misunderstanding or association with a disease condition (jaundice). Yellow fat is a genetic trait determined by a recessive gene. Alfalfa and other green feeds contain xanthophyll, a fat-soluble compound that is yellow in color. Animals with the yellow fat gene lack an enzyme that reduces (changes) the xanthophyll pigment to a colorless product. Therefore, the xanthophyll is deposited in the body fat, making it yellow. White fat in meat rabbits is preferred to

yellow fat. Plant pigments also affect urine color

Winter breeding depression

A very common occurrence in rabbitries in cold climates is a decrease in productivity during the winter. The syndrome usually has these common elements: small litters, abortions, weak litters that can't nurse, does that don't have enough milk, and does that will not breed. All of these factors lead to a decreased number of fryers toward the end of the winter. Although many causes for this syndrome have been postulated, the basic problem is inadequate nutrition.

Breeding does (and sometimes bucks) require more energy in cold weather to keep warm. If you use a restricted feeding program (rabbits are not fed all they want), increase the amount of feed in cold weather. Otherwise, the doe will not have enough food calories to provide body heat and energy for the reproduction process. Reproduction will be suspended until adequate nutrition is available, which usually occurs as warmer weather arrives.

The treatment for this syndrome is either to increase gradually the amount of feed (usually to about double) or to increase the amount of energy in the diet by increasing the amount of carbohydrate or fat.

How to pack and ship specimens for laboratory diagnosis

The best way to obtain an accurate diagnosis is to take dead animals or two or three sick animals showing typical signs to the nearest animal diagnostic laboratory and supply any additional information the pathologist may need. If delivery in person is not convenient, the dead animals can be shipped.

Shipping dead animals

If you cannot take your rabbits to a diagnostic laboratory because of distance, the next best thing is to send the dead rabbits to the laboratory.

Because it is against postal regulations to send frozen carcasses of diseased animals through the mail, shipment must be made by bus or air express. United Parcel Service will not accept carcasses. Label the outside of the box "Biological specimen," "Rush," and "Keep in a cool place."

If the carcass is to be shipped a short distance, chill (but never freeze) it thoroughly and place it in the center of a box containing sawdust or shavings. For long-distance shipments, place dry ice around the carcass, then pack it as indicated above. Never put dry ice in an airtight jar or can. If the gas cannot escape, it may cause an explosion. Properly

used, dry ice will prevent spoilage for 2 or 3 days.

Many specimens decompose after arriving at the laboratory because no one is available to take care of them promptly. With this in mind, do not send fresh specimens that will arrive on a weekend; most laboratories do not operate on Saturday or Sunday. Address the package to the laboratory itself, not to an individual employee. This will ensure more immediate attention. Do not send carcasses that have started to decompose. It is better to kill an animal or two that show typical signs, or to ship them alive if there is a chance they may reach their destination before death.

Accompanying information

Letters that do not contain sufficient information are a problem to the pathologist. In some diseases, a complete history is more useful than the carcass. The accompanying letter should contain the following information:

- Number of rabbits on the ranch
- Number of sick or dead animals
- Age and sex of affected animals
- Description of the disease as you observed it. For example, "Rabbits develop watery diarrhea, quit eating and drinking, and die in 1 or 2 days."

Use pesticides safely!

When you use any pesticide, observe these rules:

- **Wear** protective clothing and safety devices as recommended on the label. **Bathe or shower** after each use.
- **Read** the pesticide label—even if you've used the pesticide before. **Follow closely** the instructions on the label (and any other directions you have).
- **Be cautious** when you apply pesticides. **Know** your legal responsibility as a pesticide applicator. You may be liable for injury or damage resulting from pesticide use.

- Dates of first losses and subsequent losses
- Incidence of infection (whether it is in just one house or pen, or scattered throughout the rabbitry)
- What treatment, if any, has been given
- Type and brand of feed and feeding methods used for the past 6 months
- Type of housing (whether the rabbits are kept on wire or solid floors)
- Any other information that might help explain the outbreak

It is best to telephone the laboratory so the staff can be alerted to the arrival of the specimen. If they need further information, they can ask at that time.

© 2008 Oregon State University

Pacific Northwest Extension publications are jointly produced by the three Pacific Northwest states—Oregon, Washington, and Idaho. Similar crops, climate, and topography create a natural geographic unit that crosses state lines. Since 1949 the PNW program has published more than 500 titles. Joint writing, editing, and production have prevented duplication of effort, broadened the availability of faculty specialists, and substantially reduced the costs for participating states.

Published and distributed in furtherance of the Acts of Congress of May 8 and June 30, 1914, by the Oregon State University Extension Service, Washington State University Cooperative Extension, the University of Idaho Cooperative Extension System, and the U.S. Department of Agriculture cooperating.

The three participating Extension Services offer educational programs, activities, and materials—without regard to age, color, disability, gender identity or expression, marital status, national origin, race, religion, sex, sexual orientation, or veteran’s status—as required by Title VI of the Civil Rights Act of 1964, Title IX of the Education Amendments of 1972, and Section 504 of the Rehabilitation Act of 1973. The Oregon State University Extension Service, Washington State University Cooperative Extension, and the University of Idaho Cooperative Extension System are Equal Opportunity Employers.

Published September 1986. Revised January 2008.